

Fluoroscopic Analyses of Cruciate-Retaining and Medial Pivot Knee Implants

*Robert Schmidt, MD**; *Richard D. Komistek, PhD**;*
J. David Blaha, MD‡; *Brad L. Penenberg, MD§;*
and William J. Maloney, MD§§

Contemporary posterior cruciate-retaining total knee designs have provided pain relief and improved knee function but have failed to reproduce the kinematics and stability of the normal nonarthritic knee. The Medial Pivot total knee design features a near constant radius of curvature of the femoral component. The tibial surface is highly congruent and asymmetric, permitting a medial pivot motion during knee flexion. The purpose of the current study was to analyze and compare the gait kinematics of the Sigma® posterior cruciate-retaining total knee implant, the Advance® Traditional posterior cruciate-retaining total knee implant, and the Advance® Medial Pivot knee implant using flu-

oroscopic analysis. In vivo kinematics were determined for 15 clinically successful total knee arthroplasties. Five knee implants were evaluated from each group. The authors analyzed the kinematics of knee motion during the stance phase of gait for each patient. On average, subjects with the Medial Pivot knee implant had a medial pivot motion. Both posterior cruciate-retaining designs had a paradoxical roll forward of the tibia on femur during knee flexion and had greater excursion of both condyles during knee flexion than the medial pivot design. Nine of 10 of the posterior cruciate-retaining designs had condylar lift-off averaging 1.7 mm whereas only one Medial Pivot knee implant had condylar lift-off measuring 1.1 mm.

From *The Texas Hip and Knee Center, Fort Worth, TX; **Biomedical Engineering, University of Tennessee, Knoxville, TN; †Oak Ridge National Labs, Oak Ridge, TN; ‡West Virginia University, Morgantown, WV; §Cedar Sinai Medical Center, Beverly Hills, CA; and the §§Washington University School of Medicine, St. Louis, MO.

Investigation performed at The Texas Hip and Knee Center, Fort Worth, Texas, and Rose Musculoskeletal Research Laboratory, Denver, Colorado.

Funding for this study was provided by a grant from Wright Medical Technology, Inc.

Reprint requests to Robert Schmidt, MD, The Texas Hip and Knee Center, 750 Eighth Avenue, Suite 400, Fort Worth, TX 76104. Phone: 817-877-3432 or 800-356-1732; Fax: 817-877-0207; E-mail: rschmidt@caregate.net.

DOI: 10.1097/01.blo.0000063565.90853.a4

Early failures after total knee arthroplasty often were associated with component malalignment, soft tissue imbalance, or the use of constrained prostheses.^{1,14} Implant failures caused by isolated polyethylene wear were uncommon. As instrumentation and soft tissue balancing techniques improved, failure resulting from mechanical loosening declined. More recently, knee implant failures secondary to catastrophic polyethylene wear have been observed.^{2,3,17,21} These failures have been attributed to the effects of less conforming tibial articular geometries,

problems associated with polyethylene sterilization, and altered knee kinematics.

Although contemporary posterior cruciate-retaining knee designs have provided pain relief and improved knee function in most patients, these designs have failed to reproduce the kinematics and stability of the healthy nonarthritic knee. Fluoroscopic studies of contemporary cruciate-retaining knee designs have shown an absence of femoral rollback of the femur on the tibia and an irregular tibial slide forward as the knee approaches 20° flexion. In addition, a significant number of cruciate-retaining designs, when evaluated fluoroscopically, have shown edge loading that can predispose to accelerated polyethylene wear.^{19,20}

The design of the Medial Pivot total knee arthroplasty reflects contemporary data regarding knee kinematics.^{9,12} Magnetic resonance imaging (MRI) of knees from cadavers showed an absence of anteroposterior (AP) motion of the medial femoral condyle and posterior translation of the lateral femoral condyle during knee flexion.¹² The Medial Pivot femoral component has a C-curve design with a near constant radius of curvature of the distal and posterior femur. The tibial component is asymmetric with a highly conforming medial aspect. This design permits posterior rolling and sliding of the lateral femoral condyle around a stable spinning medial femoral condyle during knee flexion. The epicondylar axis of the femur serves as the axis of rotation of the Medial Pivot implant. In theory, these design features lower the contact stresses on the tibial surface, providing for enhanced durability of the polyethylene.

The purpose of the current study was to analyze and compare the gait kinematics of the Sigma® posterior cruciate-retaining total knee implant (Johnson & Johnson Professional, Inc, Raynham, MA), the Advance® Traditional posterior cruciate-retaining total knee implant (Wright Medical Group, Inc, Memphis, TN), and the Medial Pivot knee implant (Wright Medical Group, Inc) using fluoroscopic analysis.

MATERIALS AND METHODS

In vivo kinematics were determined for 15 subjects who had a total knee arthroplasty. The mean followup of the patients was 2 years, 2 months. Five patients received an Advance® Medial Pivot knee arthroplasty, five patients received the Sigma® posterior cruciate-retaining prosthesis, and five patients received the Advance® Traditional posterior cruciate-retaining knee arthroplasty. All 15 patients were diagnosed as having primary osteoarthritis of the knee. For patients receiving an Advance® Medial Pivot knee implant, the average age was 68 years and the average height and weight were 5'9" and 211 lb, respectively. The average preoperative range of motion (ROM) measured 119°, and the average postoperative ROM measured 118°. The average preoperative Knee Society rating score was 66 points, and the postoperative Knee Society rating score before the study was 93 points.¹¹

For patients receiving the posterior cruciate-retaining prostheses, the average age was 65 years, and the average height and weight were 5'9" and 197 lb, respectively. The average preoperative ROM measured 116°, and the average postoperative ROM measured 111°. The average preoperative Knee Society score was 64 points, and the postoperative Knee Society rating score before the study was 96 points. The same surgeon did all the surgeries. In all 15 knees, the posterior cruciate ligament was preserved. The subjects were selected randomly according to their willingness to participate in the study.

Each subject was asked to do normal gait under fluoroscopic surveillance in the sagittal plane. The in vivo kinematics for each subject was determined using a three-dimensional interactive model-fitting process.^{4-6,8} (Dennis DA, Komistek RD, Sarojak ME, Hoff WA, Stiehl JB: Assessment of 3D normal knee kinematics under in vivo conditions during multiple weight-bearing activities. Presented at the Sixty-Seventh Annual Meeting of the American Academy of Orthopaedic Surgeons, Orlando, March 2000; Komistek RD, Dennis DA, Walker SA, Anderson DT, Laughlin M: In Vivo Analysis of Tibiofemoral Rotation: Does Screw Home Rotation Occur After TKA? Presented at the Annual Meeting of the American Academy of Orthopaedic Surgeons, New Orleans, 1998.) The process was done at heel strike, 33% and 66% of stance-phase, and toe-off. Initially, AP contact position was assessed.⁴⁻⁶ (Dennis DA, Komistek RD, Sarojak ME,

Hoff WA, Stiehl JB: Assessment of 3D normal knee kinematics under in vivo conditions during multiple weight-bearing activities. Presented at the Sixty-Seventh Annual Meeting of the American Academy of Orthopaedic Surgeons, Orlando, March 2000; Komistek RD, Dennis DA, Walker SA, Anderson DT, Laughlin M: In Vivo Analysis of Tibiofemoral Rotation: Does Screw Home Rotation Occur After TKA? Presented at the Annual Meeting of the American Academy of Orthopaedic Surgeons, New Orleans, 1998.) To determine AP position, a reference line was constructed across the tibia base-plate in the coronal plane and was defined as the 0 position. A contact anterior to the 0 reference was denoted as a positive contact position, and a contact posterior to this axis was denoted as a negative contact position. Next, the image was reoriented in a pure coronal view so that axial rotation of the femoral component could be assessed with respect to the tibial component. Similar to the normal knee, if the tibia internally rotated with respect to the femur with increasing knee flexion, the rotation was denoted as positive.⁷ (Dennis DA, Komistek RD, Sarojak ME, Hoff WA, Stiehl JB: Assessment of 3D normal knee kinematics under in vivo conditions during multiple weight-bearing activities. Presented

at the Sixty-Seventh Annual Meeting of the American Academy of Orthopaedic Surgeons, Orlando, March 2000.) In assessing rotation angles, if the tibial contact position was anterior of the medial contact position, the rotation angle was denoted as negative, and if the lateral condyle was posterior of the medial condyle, the rotation angle was denoted as positive. Finally, the distances from the medial and lateral condyles to the tibial plateau were measured to assess for condylar lift-off. If the difference between the two measurements was greater than 1 mm, then condylar lift-off was denoted.

Three separate error analyses were conducted to evaluate the accuracy of the model-fitting process.^{8,16,18} The relative error, derived for all three experiments was consistently less than 0.5° in rotation and 0.5 mm in translation.

RESULTS

Anteroposterior Translation

On average, subjects having an Advance® Medial Pivot total knee arthroplasty experienced minimal motion of the medial condyle during gait (Fig 1). The medial condyle contact

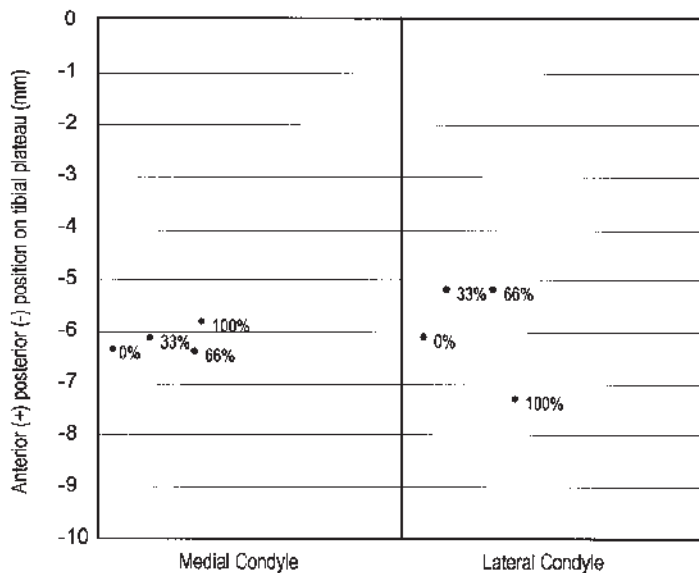


Fig 1. Knee kinematics were assessed during the following phases of stance gait: 0% (heel strike), 33% of stance phase, 66% of stance phase, and 100% (toe-off). The average medial and lateral condyle contact positions are shown for subjects with a Medial Pivot total knee arthroplasty.

position moved minimally throughout the stance phase of gait. At heel strike, the medial condyle contact position was a mean -6.3 mm (range, -5.1 – -6.9 mm). At 33% of stance phase, the contact position was a mean -6.1 mm (range, -4.6 – -6.7 mm), and at 66% of stance phase, the contact position was a mean -6.3 mm (range, -5.2 – -6.8 mm). At toe-off, the medial condyle contact position was a mean -5.8 mm (range, -4.9 – -6.6 mm).

The Advance® Medial Pivot lateral condyle moved during the stance phase of gait, rotating around the medial condyle. At heel strike the lateral condyle contact position was a mean -6.1 mm (range, -1.2 – -11.0 mm). At 33% stance phase, the lateral condyle contact position was a mean -5.2 mm (range, -0.4 – -10.1 mm), and at 66% stance phase, the contact position was a mean -5.2 mm (range, -0.4 – -10.5 mm). At toe-off, the lateral condyle contact position was a mean -7.3 mm (range, -3.0 – -13.9 mm).

On average, the medial contact positions for patients with the Sigma® posterior cruciate-

retaining total knee arthroplasty were -5.4 mm at heel strike (range, -4.0 – -8.0 mm), -6.7 mm at 33% stance phase (range, -4.2 – -10.5 mm), -6.5 mm at 66% stance phase (range, -4.9 – -7.6 mm), and -5.5 mm at toe-off (range, -4.3 – -7.2 mm). On average, these patients had more motion of the lateral condyle than the medial condyle during the stance phase of gait (Fig 2). From heel strike to toe-off, these patients, on average, experienced a rotation of their lateral condyle around the medial condyle. Patients with the Sigma® posterior cruciate-retaining total knee arthroplasty also had more variability in kinematic patterns than patients with a Medial Pivot total knee arthroplasty. Although the patients with the Sigma® posterior cruciate-retaining arthroplasty had more lateral motion than medial motion on average, only three of the five patients actually experienced rotation of the lateral condyle around the medial condyle from heel strike to toe-off.

As observed with the patients with the Medial Pivot arthroplasty, the patients with Sigma®

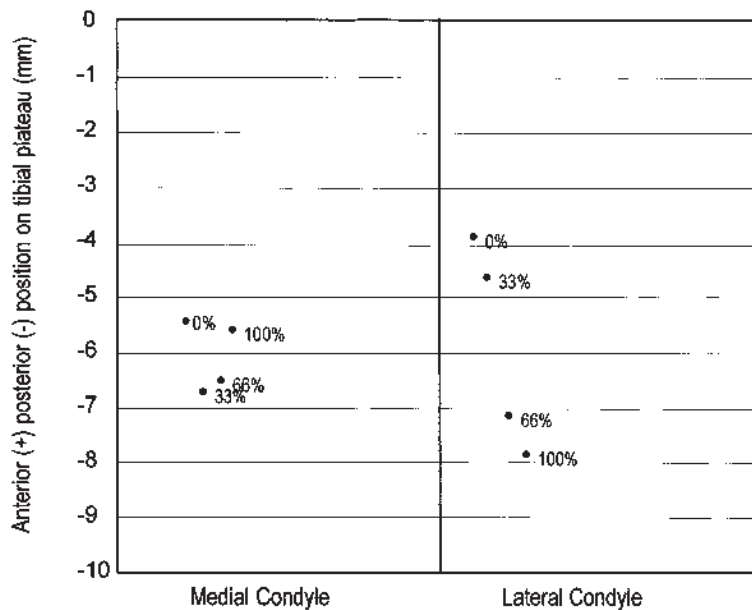


Fig 2. The average medial and lateral condyle contact positions are shown for subjects with a Sigma posterior cruciate-retaining total knee arthroplasty at heel strike (0%), 33% of stance phase, 66% of stance phase, and toe-off (100%).

posterior cruciate-retaining arthroplasties had more motion of the lateral condyles than the medial condyles. The mean contact positions were -3.8 mm at heel strike (range, -1.4--5.9 mm), -4.6 mm at 33% stance phase (range, -1.2--7.6 mm), -7.1 mm at 66% stance phase (range, -2.5--12.3 mm), and -7.8 mm at toe-off (range, -5.6--13.0 mm).

On average, subjects having an Advance® Traditional posterior cruciate-retaining total knee arthroplasty experienced similar amounts of motion of their medial and lateral condyles (Fig 3). Therefore, because the medial and lateral condyles experienced minimal motion on average, a medial pivot motion did not occur for subjects having Traditional Advance® posterior cruciate-retaining total knee arthroplasties. Two subjects experienced more motion of their lateral condyle than of their medial condyle, two subjects experienced more medial condyle motion than lateral condyle motion, and one subject experienced similar motion of the medial and lateral condyles from heel strike to toe-off. On average, at

heel strike the medial condyle contact position was -6.7 mm (range, -1.4--8.9 mm), -7.3 mm (range, -6.7--8.6 mm) at 33% stance phase, -6.0 mm (range, -3.8--8.2 mm) at 66% stance phase, and -6.2 mm (range, -2.2--8.3 mm) at toe-off. The average lateral condyle contact position was -4.7 mm (range, -0.6--7.7 mm) at heel strike, -3.6 mm (range, -1.6--6.2 mm) at 33% stance phase, -4.8 mm (range, -3.7--6.5 mm) at 66% stance phase, and -4.4 mm (range, -0.7--8.3 mm) at toe-off.

Axial Tibiofemoral Rotation

Subjects having either an Advance® Medial Pivot or Sigma® posterior cruciate-retaining total knee arthroplasty experienced, on average, a normal axial tibiofemoral rotation during stance phase of gait (Figs 4, 5). Patients with a Medial Pivot implant had the following axial rotation angles: -0.2° at heel strike (range, -7.1°-5.6°); -1.2° at 33% stance phase (range, -8.2°-4.9°); -1.4° at 66% stance phase (range, -8.3°-4.9°); and 1.9° at

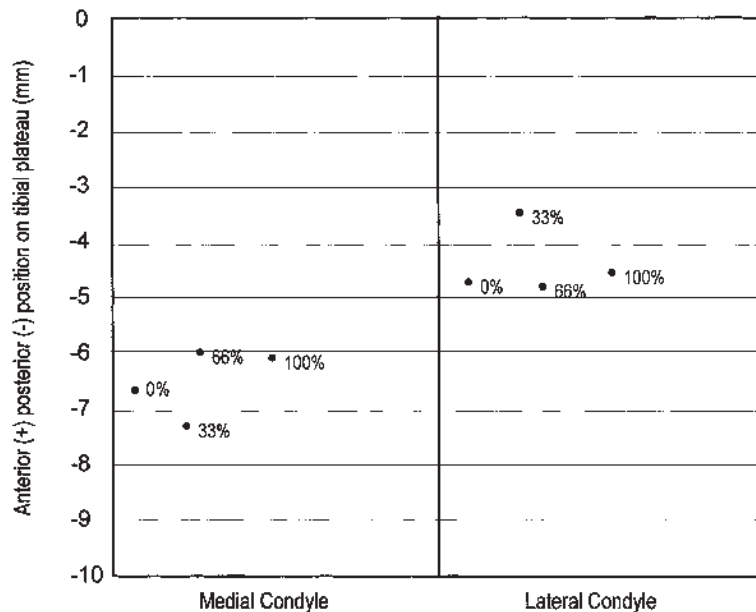


Fig 3. The average medial and lateral condyle contact positions for subjects having an Advance Traditional posterior cruciate-retaining total knee arthroplasty are shown at 0% (heel strike), 33%, 66%, and 100% (toe-off) of stance phase.

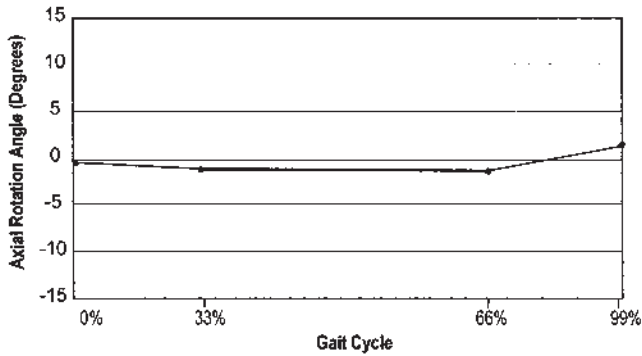


Fig 4. The average axial rotation angles are shown for patients with an Advance Medial Pivot total knee arthroplasty.

toe-off (range, -4.8° – 10.0°). Therefore, the average total axial rotation from heel strike to toe-off was 2.2° (range, -0.2° – 4.5°). Three of the five subjects had normal axial tibiofemoral rotation, whereas two subjects had a small amount of opposite rotation (-0.2° and -0.1°).

On average for subjects having a Sigma® posterior cruciate-retaining total knee arthroplasty, the axial rotation angles were -2.0° at heel strike (range, -4.7° – 1.5°), -2.8° at 33% stance phase (range, -9.8° – 2.5°), 0.8° at 66% stance phase (range, -5.7° – 8.0°), and 2.9° at toe-off (range, -1.2° – 7.5°). Therefore, the average total axial rotation from heel strike to toe-off was 4.9° (range, 0.4° – 11.6°). All of the five subjects having a Sigma® posterior cruciate-retaining total knee arthroplasty had normal axial tibiofemoral rotation patterns during stance phase of gait.

On average, subjects having an Advance® Traditional posterior cruciate-retaining total knee arthroplasty had minimal axial tibio-

femoral rotation from heel strike to toe-off (Fig 6). The average axial rotation angles for subjects having an Advance® posterior cruciate-retaining total knee arthroplasty were -2.6° (range, -9.3° – 5.1°) at heel strike, -4.8° (range, -9.2° – -0.7°) at 33% stance phase, -1.6° (range, -6.0° – 2.1°) at 66% stance phase, and -2.4° (range, -5.8° – 1.4°) at toe-off. Therefore, the average total axial rotation from heel strike to toe-off was only 0.3° (range, -7.1° – 5.5°). Only three of the subjects had normal axial tibiofemoral rotation from heel strike to toe-off. Unlike the Medial Pivot total knee arthroplasty, where two of the subjects experienced minimal axial rotation, two subjects having a Traditional posterior cruciate-retaining total knee arthroplasty had significant opposite axial rotation from heel strike to toe-off (-4.4° and -7.1°). Unlike the subjects having either an Advance® Medial Pivot or Sigma® posterior cruciate-retaining total knee arthroplasty, on average, subjects having

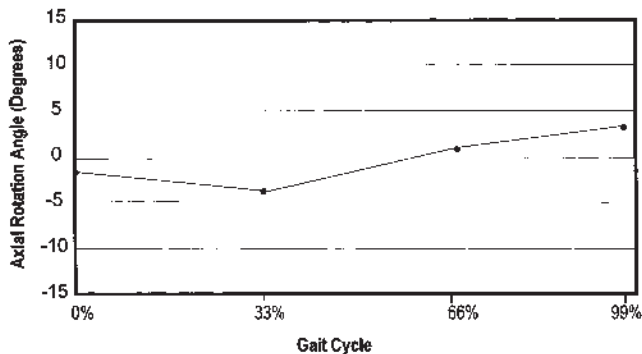


Fig 5. The average axial rotation angles are shown for patients with a Sigma posterior cruciate-retaining total knee arthroplasty.

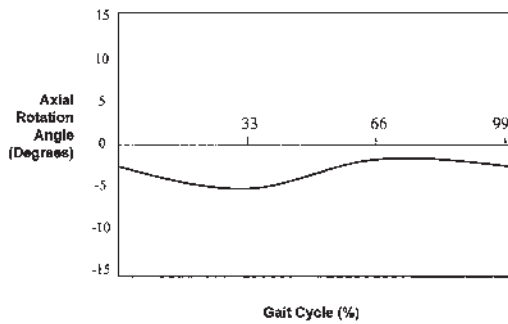


Fig 6. Average axial rotation angles are shown for subjects having an Advance Traditional posterior cruciate retaining total knee arthroplasty.

an Advance® Traditional posterior cruciate-retaining total knee arthroplasty had a negative axial rotation angle throughout the stance phase of gait.

Condylar Lift-Off

Only one patient with an Advance® Medial Pivot implant had condylar lift-off. Lift-off measured 1.1 mm laterally and occurred at heel strike. In contrast, all five patients with a Sigma® posterior cruciate-retaining component had condylar lift-off, which occurred predominantly at heel strike (average lift-off, 1.4 mm) or toe-off (average lift-off, 1.6 mm). The maximum amount of lift-off for patients with a Sigma® posterior cruciate-retaining total knee arthroplasty was 1.9 mm (lateral), 1.8 mm (medial), 1.5 mm (lateral), 2.2 mm (medial), and 2.1 mm (lateral).

Four of the five subjects having an Advance® Traditional posterior cruciate-retaining total knee arthroplasty experienced condylar lift-off. The maximum amount of lift-off was 1.6 mm (medial), 1.5 mm (lateral), 1.2 mm (medial), and 1.1 mm (medial) for the four subjects having lift-off. In previous studies of posterior cruciate-retaining total knee arthroplasties, femoral lift-off occurred predominantly with the lateral condyle. In this instance, three of the four subjects experiencing condylar lift-off having an Advance® Traditional posterior cruciate-retaining total knee arthroplasty had lift-off on the medial side.

DISCUSSION

Retention of the posterior cruciate ligament in total knee arthroplasty theoretically improves the efficiency of the extensor mechanism, prevents subluxation of the tibia on the femur, and permits rollback of the tibia during knee flexion. Multiple fluoroscopic studies of posterior cruciate-retaining knee prostheses, however, have shown the absence of femoral rollback during knee flexion and the presence of an irregular forward translation of the tibia on femur.^{19,20}

The purpose of the current study was to evaluate the Medial Pivot total knee arthroplasty in vivo using fluoroscopic analysis to determine whether a medial pivot motion occurs during knee flexion and compare the Medial Pivot total knee arthroplasty with two conventional posterior cruciate-retaining designs. On average, patients having the Advance® Medial Pivot and the posterior cruciate-retaining Sigma® total knee arthroplasties had medial pivot motion during fluoroscopic gait analysis. Patients with the Medial Pivot knee arthroplasty, however, had less variability of AP motion than patients with a Sigma® posterior cruciate-retaining design. On average, patients with the Sigma® knee implant or the Advance® Traditional posterior cruciate-retaining total knee arthroplasty had enhanced excursion of both condyles as compared with patients with the Medial Pivot design. Patients with the Medial Pivot design had, on average, greater excursion of the lateral condyle around a medial condyle which moved minimally. Patients with the Sigma® design knee or the Advance® Traditional posterior cruciate-retaining total knee arthroplasty had a more pronounced paradoxical motion of the tibia on the femur during knee flexion.

Although the patients with the Medial Pivot knee arthroplasty had a medial pivot motion, the arc of posterior translation of the lateral condyle measured on average less than 3 mm. In the current study, the stance phase of gait was evaluated and a normal or anticipated arc of medial pivot motion has not been established. Posterior translation of the lateral condyle

during knee motion may be affected by differences in dynamic stability of the knee in different subjects, retention of the posterior cruciate ligament, and whether gait analysis was done on flat or uneven ground. The data points show AP stability of the medial femoral condyle and posterior translation of the lateral femoral condyle during knee flexion.

With the Advance® Medial Pivot and Sigma® posterior cruciate-retaining implants, patients had a near normal axial tibiofemoral rotation. Only three of the patients receiving the Advance® Traditional total knee arthroplasty had normal axial tibiofemoral rotation from heel strike to toe-off. Two of the patients with Advance® Traditional total knee arthroplasties had a negative axial rotation angle throughout the stance phase of gait. This phenomenon may be caused by the relative increased congruency of the femorotibial articulation associated with this design combined with retention of the posterior cruciate ligament.

Ligamentous balance, the position and rotation of the implanted components, and the direction of resultant muscle forces across the knee during flexion all may contribute to femoral component lift-off during gait. Lift-off after a posterior cruciate-retaining total knee arthroplasty occurs primarily laterally, resulting in high polyethylene stresses medially.⁶ During the midstance phase of gait, the medial compressive loads across the knee increase 70% to 75%.^{10,13} These factors may contribute to accelerated wear and polyethylene failure of the posterior medial joint compartment.¹⁵

All of the patients receiving the Sigma® knees had condylar lift-off averaging 1.9 mm. Four of the five patients receiving the Advance® Traditional total knee arthroplasty also had condylar lift-off averaging 1.3 mm. Only one of the five patients with Medial Pivot total knee arthroplasties had lift-off, and the lift-off measured 1.1 mm.

In a previous study, Dennis et al⁶ identified lift-off in 75% of patients studied after primary total knee arthroplasty. The 40-patient cohort was divided equally between patients receiving posterior cruciate-retaining

and posterior-stabilized total knee arthroplasties. The reduced frequency of lift-off associated with the Medial Pivot total knee arthroplasty seems secondary to the asymmetric design of the tibial component. The significant congruency of the femorotibial articulation medially results in an enhanced contact area that may resist the tendency to lift-off as medial compressive loads increase.

These preliminary data suggest that the Medial Pivot total knee arthroplasty shows a medial pivot motion during the stance phase of gait with a lower frequency of condylar lift-off than conventional posterior cruciate-retaining designs. These factors may contribute to reduced polyethylene wear. Correlation with long-term clinical outcomes is necessary to validate the efficacy of this newer design.

References

1. Bertin KC, Freeman MAR, Samuelson KM, Ratcliffe SS, Todd RC: Stemmed revision arthroplasty for aseptic loosening of total knee replacement. *J Bone Joint Surg* 67B:242–248, 1985.
2. Cadambi A, Engh GA, Dwyer KA, et al: Osteolysis of the distal femur after total knee arthroplasty. *J Arthroplasty* 9:579–594, 1994.
3. Chiba J, Schwedeman LJ, Booth Jr RE, et al: A biomechanical, histologic, and immunohistologic analysis of membranes obtained from failed cemented and cementless total knee arthroplasty. *Clin Orthop* 299:114–124, 1994.
4. Dennis DA, Komistek RD, Colwell CE, et al: In vivo anteroposterior femorotibial translation of total knee arthroplasty: A multicenter analysis. *Clin Orthop* 356:47–57, 1998.
5. Dennis DA, Komistek RD, Hoff WA, Gabriel SM: In vivo knee kinematics derived using an inverse perspective technique. *Clin Orthop* 331:107–117, 1996.
6. Dennis DA, Komistek RD, Walker SA, Cheal EJ, Stiehl JB: Femoral condylar lift-off in vivo total knee arthroplasty. *J Bone Joint Surg* 83B:33–39, 2001.
7. Hill PF, Williams VV, Iwaki H, Pincerova V, Freeman MAR: Tibiofemoral movement 2: The loaded and unloaded living knee studies by MRI. *J Bone Joint Surg* 82B:1196–1200, 2000.
8. Hoff WA, Komistek RD, Dennis DA, et al: Pose estimation of artificial knee implants in fluoroscopy images using a template matching technique. Proceedings of the Third Workshop on Applications of Computer Vision, Institute of Electrical and Electronics Engineers, Inc, Sarasota, FL 181–186, 1996.
9. Holister AM, Jatana S, Singh AK, Sullivan WW, Lupichuk AG: The axes of rotation of the knee. *Clin Orthop* 290:259–268, 1993.
10. Hsu RWW, Himeno S, Coventry MB, Chao EYS:

- Normal axial alignment of the lower extremity and load-bearing distribution at the knee. *Clin Orthop* 255:215–227, 1990.
11. Insall JN, Dorr LD, Scott RD, Scott WN: Rationale of the Knee Society clinical rating system. *Clin Orthop* 248:13–14, 1989.
 12. Iwaki H, Pinskerova V, Freeman MA: Tibiofemoral movement 1: The shapes and relative movements of the femur and tibia in the unloaded cadaver knee. *J Bone Joint Surg* 82B:1189–1195, 2000.
 13. Johnson F, Leitl S, Waugh W: The distribution of load across the knee: A comparison of static and dynamic measurements. *J Bone Joint Surg* 62B:346–349, 1980.
 14. Lewallen DG, Bryan RS, Peterson FA: Polycentric total knee arthroplasty. *J Bone Joint Surg* 66A:1211–1218, 1984.
 15. Lewis P, Rorabeck CH, Bourne RB, Devane P: Posteromedial tibial polyethylene failure in total knee replacements. *Clin Orthop* 299:11–17, 1994.
 16. Mahfouz M: In vivo estimation of six degrees of freedom position and orientation for non-implanted human joints from single plane fluoroscopy. PhD Dissertation. Golden, CO, Colorado School of Mines, Engineering 2001.
 17. Peters Jr PC, Engh GA, Dwyer KA, et al: Osteolysis after total knee arthroplasty without cement. *J Bone Joint Surg* 74A:864–876, 1992.
 18. Sarojak ME: Model-fit: An interactive pose determining system. Engineering Thesis. Golden, CO, Colorado School of Mines, 1998.
 19. Stiehl JB, Komistek RD, Cloutier JM, Dennis DA: The cruciate ligament in total knee arthroplasty: A kinematic analysis of 2 total knee arthroplasties. *J Arthroplasty* 15:545–550, 2000.
 20. Stiehl JB, Komistek RD, Dennis DA, et al: Fluoroscopic analysis of kinematics after posterior-cruciate-retaining knee arthroplasty. *J Bone Joint Surg* 77B:884–889, 1995.
 21. Wright TM, Bartel DL: The problem of surface damage in polyethylene total knee components. *Clin Orthop* 205:67–74, 1986.